

Venoms from stingrays (Class Chondrichthyes: Myliobatiformes) and fish (Osteichthyes: Actinopterygii) for possible therapeutics.

Carlos Henrique Marchiori¹

¹ Instituto Federal Goiano

Potential competing interests: No potential competing interests to declare.

Marco Vinícios de Oliveira Santana¹, Klebert de Paula Malheiros¹

¹Department of Biology and Medicine of the Marco Santana Institute, Goiânia, Goiás, Brazil.

The niquim *Thalassophryne nattereri* Steindachner, 1876 (Actinopterygii: Batrachoidiforme: Batrachoididae) It is a fish with calm habits and the venom is inoculated into the victim, usually, bathers and fishermen who step on the animal. Niquim is found throughout the Northeast region of Brazil, both in fresh and salt water. Accidents occur more frequently in rivers where this animal is present. Its appearance is almost identical to that of the pacamão, but it does not grow as much and its body is slightly reddish. lives mainly in brackish waters, common in regions where sea and river waters meet. It is approximately 15 centimeters long, is wider at the level of the pectoral fins, is thinner at the back, and does not have scales but is covered in mucus (Figure 1) [1-3].



Figure 1. Researchers from Butantan, who had developed a solution against niquim stings, discovered in the fish's venom a peptide with anti-inflammatory activity for multiple sclerosis *Thalassophryne nattereri* Steindachner, 1876 (Actinopterygii: Batrachoidiforme: Batrachoididae) and its poisonous spines. In another study, the group of researchers had already observed a peptide in niquim. Source: Divulgação Agência FAPESP and <https://agencia.fapesp.br/peixe-peconhento-tem-molecula-com-acao-potencial-contra-esclerose/24058>.

1. Therapeutic: The peptide in niquim venom was shown to have an action against multiple sclerosis a neurological autoimmune inflammatory disease in which the immune system affects the myelin sheath that covers neurons, responsible for nerve conduction [1-4].

Generally, part of its body enters the sand, in shallow waters, and is quite resistant. It can stay out of the water for eight to 12 hours. Due to its grayish color, it is common to be confused with sand. It has two spines in the dorsal region and one on each side, covered by a venom gland. These spines are hollow and when the fish is under pressure, for example when stepped on, the gland descends and the venom is released through the spine. It contracts the muscles of the glands that inject venom through four hollow spines, two on the sides of the body and two on the back. This is what hurts the most when someone steps on the animal without realizing it (Figure 2) [4-7].

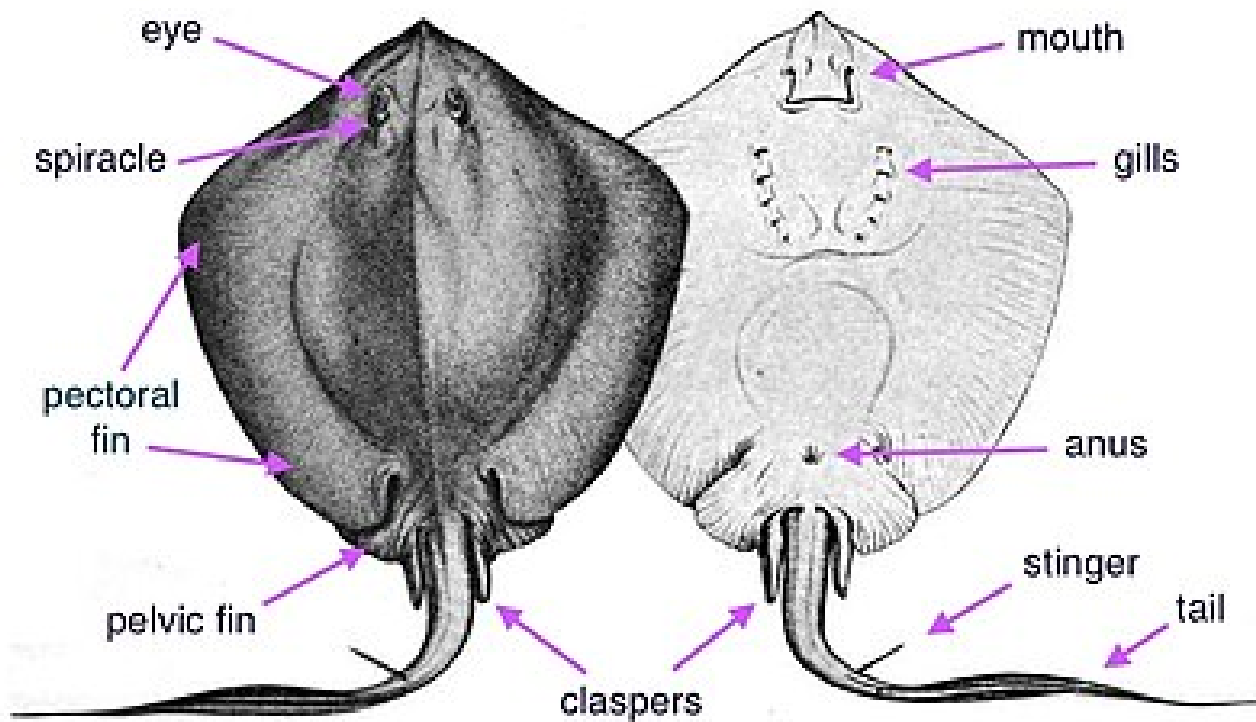


Figure 2. dorsal (topside) ventral (underside). External anatomy of a male bluntnose stingray *Hypanus say* (Lesueur, 1817). (Elasmobranchii: Myliobatiformes: Dasyatidae). Source: <https://en.wikipedia.org/wiki/Stingray>.

Stingrays, common in the north of the country, are quite dangerous. Common in both rainwater and marine waters, stingrays have a stinger in their tail capable of causing edema, hemorrhages, and necrosis. If it didn't have the venom, the stingray would already cause serious injuries because the animal, when it feels threatened, uses its tail, which is like a whip, large and serrated, causing cuts. The poisons are made up of proteins and added to the toxins in fish skin mucus, which normally protect the animals against pathogens. In some fish, such as stingrays, the stinger is covered by the skin and covered in mucus (Figure 3) [5-9].

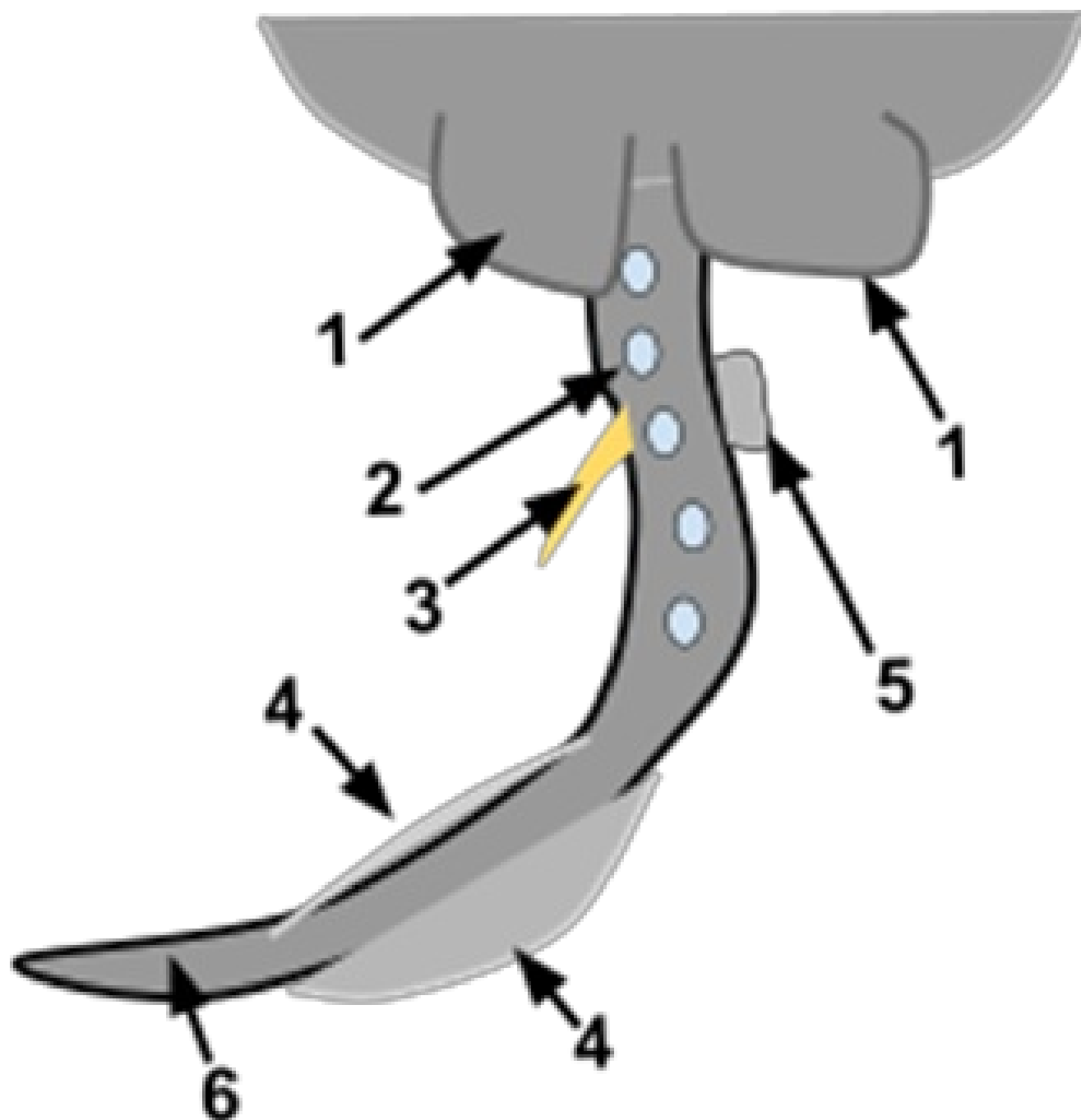


Figure 3. Posterior anatomy of a stingray. (1) Pelvic Fins (2) Caudal Tubercles (3) Stinger (4) Dorsal Fin (5) Claspers (6) Tail. Source: <https://en.wikipedia.org/wiki/Stingray>.

Few people know, but some representatives of this group of animals also have venom and can inoculate victims with substances. This is the case, for example, of some catfish, stingrays, and niquim, the latter being one of the focuses of research in Butantan. Along with stingrays and catfish, niquim is among the main causes of accidents among Brazilian fish [7-9].

There are several species of fish from the Batrachoididae family on the Brazilian coast, but *T. nattereri* is the most

common. Brazilian toadfish are small to medium in length, approximately 15 cm, and are numerous in estuarine areas. Its venomous apparatus has two dorsal fins and two gills that cover hollow needle-shaped spines with poisonous glands at the base. The fish remains motionless in sandy or muddy bottoms and the venom is injected into the victim through the spines when the gland is pressed. Experimental studies on the venom report the development of a potential antiserum to neutralize the nociceptive, edematogenic, and necrotic effects of the venom [9-12].

This species, whose scientific name is *T. nattereri*, usually lives in slightly salty waters, in the transition between rivers and seas. It is mostly found in the Northeast region of Brazil. The issue is that the niquim likes to stay buried in the sand and an unsuspecting passerby ends up stepping on the fish's spines, located on the sides and upper part of the animal's body, through which the poison passes. When analyzing the poison inoculated by niquim, Butantan specialists identified TnP, which stands for *Thalassophryne nattereri* peptide. When analyzing the venom inoculated by niquim, experts from Butantan identified TnP, which stands for *Thalassophryne nattereri* peptide (Figure 4) [11-14].

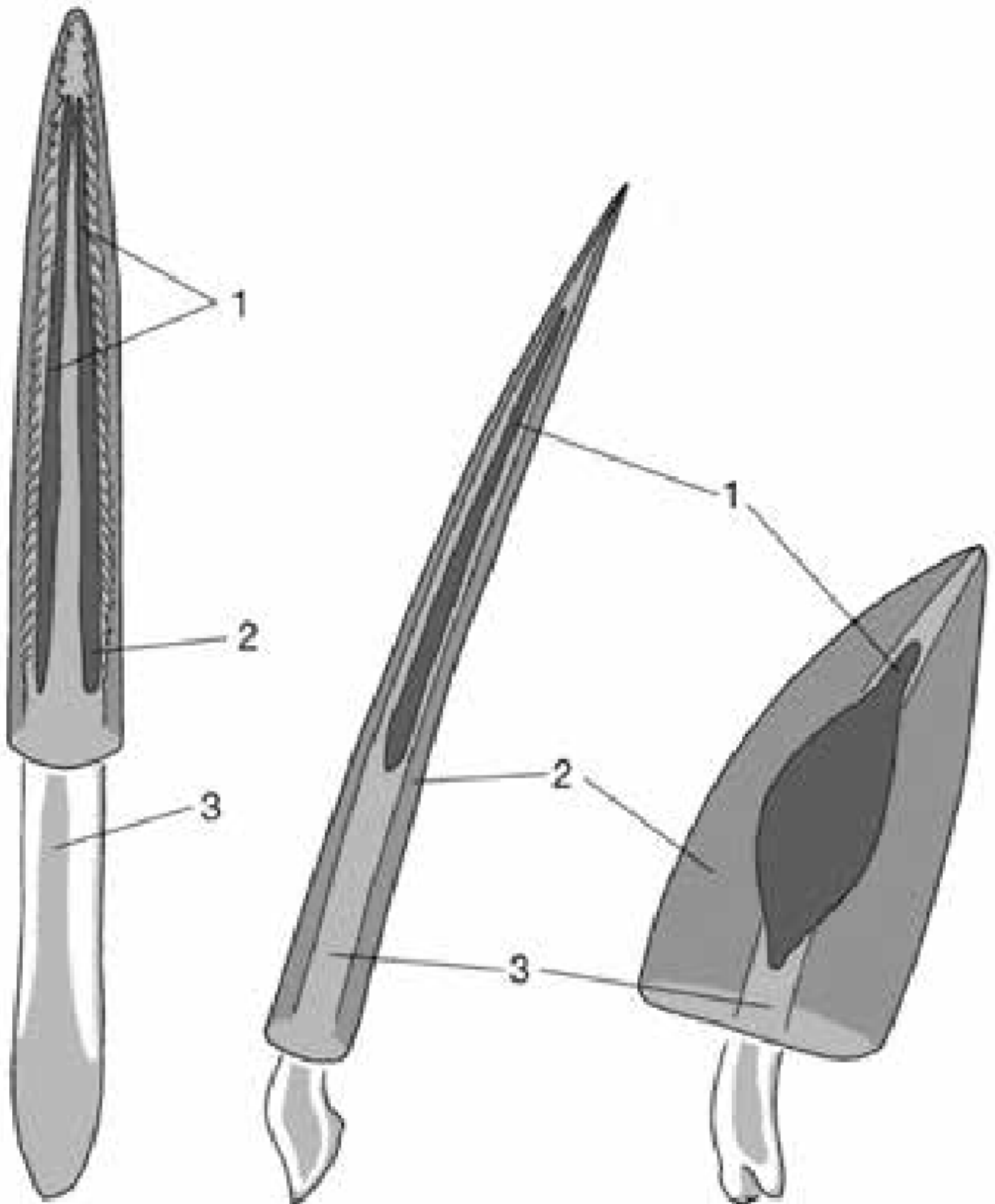


Figure 4. Venom apparatus of various venomous extant fish. (A) The tail spine of a stingray. On the ventral side, there are two venom glands arranged in pairs. The spine is serrated and can cause deep wounds. (B) The dorsal spine of a

lionfish (*Pterois* sp.). There is a narrow venom gland on both sides of the slender spine. The spine and glands are surrounded by a fine integument. (C) The dorsal spine of a stonefish (*Synanceia* sp.). A massive bony ray with a large venom gland on both sides that is surrounded by a sturdy integument. 1, venom gland; 2, integument (enveloping the sheath). 3, calcified cartilaginous spine (leftmost) or bony spines (right). Sources: (from Halstead, 1988, modified) and https://www.researchgate.net/figure/Venom-apparatus-of-various-venomous-extant-fish-from-Halstead-1988-modified-A-Tail_fig4_330841432.

They chemically synthesized the molecule and began carrying out the first tests in the laboratory. In rodents, the substance was able to treat inflammatory conditions similar to asthma and multiple sclerosis, a disease that affects the central nervous system. This is precisely where the second fish comes into the story: the zebrafish *Danio rerio* (Hamilton, 1822) (Cypriniformes: Cyprinidae) is used as an experimental model in tests with TnP (Figure 5) [11-14].

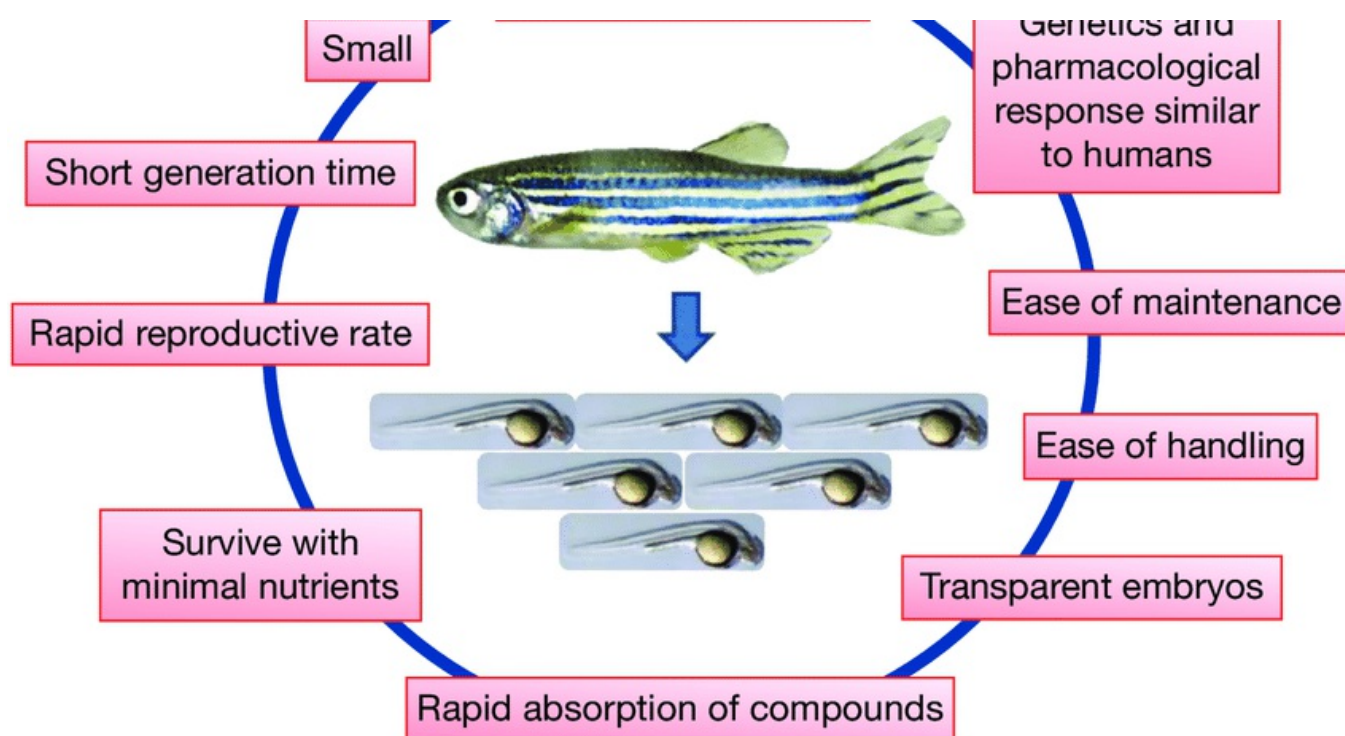


Figure 5. Characteristics of the *Danio rerio* (Hamilton, 1822) (Cypriniformes: Cyprinidae) model that enhances the efficiency of bioactive molecule discovery from natural products 58 Small amount of test compounds required.

Source: [researchgate.net/figure/Characteristics-of-the-Danio-rerio-model-that-enhances-the-efficiency-of-bioactive_fig4_236466359](https://www.researchgate.net/figure/Characteristics-of-the-Danio-rerio-model-that-enhances-the-efficiency-of-bioactive_fig4_236466359).

Another study object is the mucus covering the bodies of niquim catfish and stingrays. The substance has antimicrobial action which, in the future, could be used to develop medicines or better understand the mechanism of protection against bacteria. Studies show that species of gram-negative bacteria such as *Acinetobacter* spp., *Pseudomonas aeruginosa*, *Klebsiella pneumoniae*, *Klebsiella oxytoca*, *Serratia* spp., *Shigella* spp., and *Enterobacter* spp. are found only in mucus, while *Plesiomonas shigelloides* and *Citrobacter koseri* are found only in water. The bacteria found in both water and

mucus are *Aeromonas hydrophila*, *Aeromonas sobria*, *Pseudomonas putida*, *Clostridium freundii*, *Escherichia coli*, and *Enterobacter cloacae* [14-19].

2. Therapeutic possibility: Antimicrobial.

Potamotrygon motoro (Müller and Henle, 1841) (Chondrichthyes: Potamotrygonidae) is known with peacock-eyed stingray and motor aqraia fishbone to three barbed in the mid-distal region of the tail. These are covered by secretory cells that produce various proteins with nociceptive, inflammatory, and necrotic actions. Additionally, stingrays, like other fish, are covered in mucus. Although mucus contains elements of the nonspecific immune system, it also harbors bacteria of various types. The stingers, with their associated secretory cells and mucus, constitute the only physical defense weapon of these fish (Figure 6) [15-19].




Figure 6. An adult ocellate river stingray *Potamotrygon motoro* (Müller and Henle, 1841) (Chondrichthyes: Potamotrygonidae) from the Araguaia-Tocantins basin. Source: Photo: Itamar Júnior Tonial (2013).

Isolated a compound from *P. motoro* stings that contracted guinea pig ileum and produced a lethal vasodilation in rats. He concluded that the active constituent is non-proteinaceous, non-lipidic, water-insoluble, thermostable, and parasympathomimetic. Centrifuging the solution caused a significant reduction in the activity of the supernatant, suggesting that the active principle was suspended, rather than *Potamotrygon motoro* dissolved 5'-nucleotidase,

phospholipase, acid phosphatase, hyaluronidase, caseinolytic, gelatinolytic, and elastinolytic activities were detected in *P. motoro* venom from animals collected in the Crixás-Açu River (Goiás, Brazil) (Figure 7) [16-19].

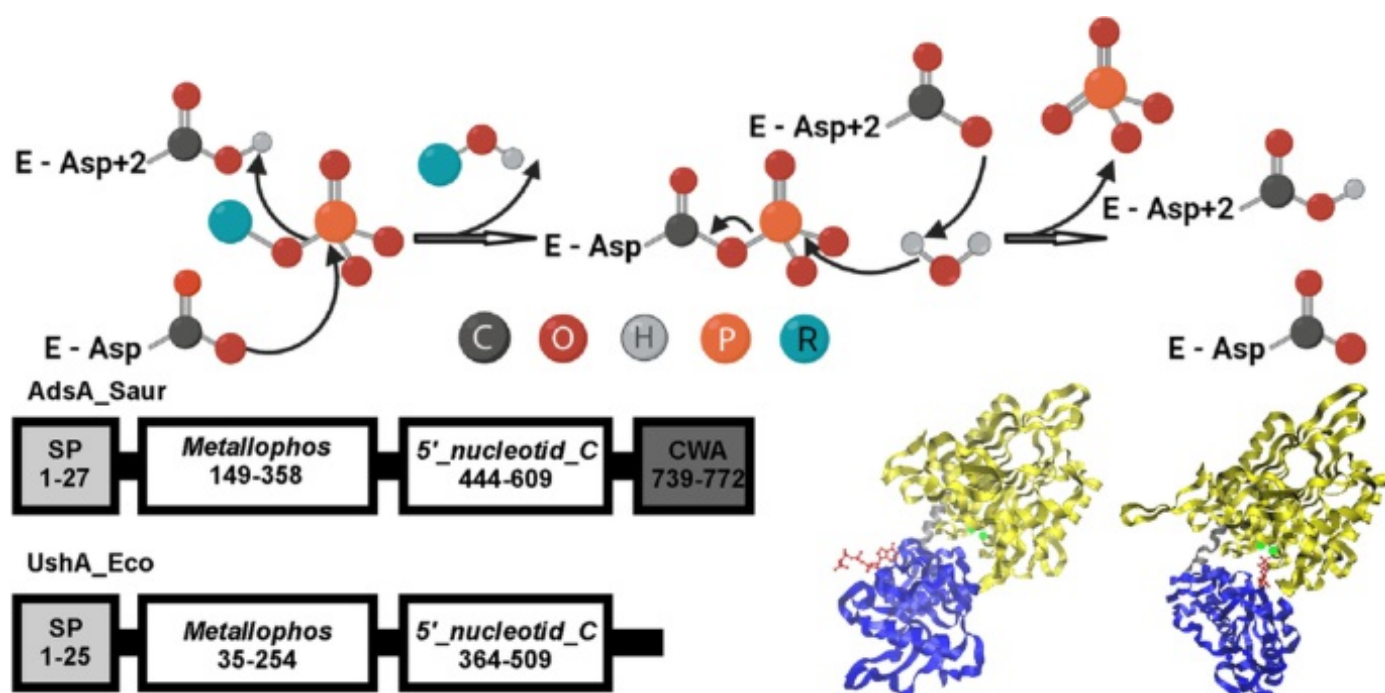
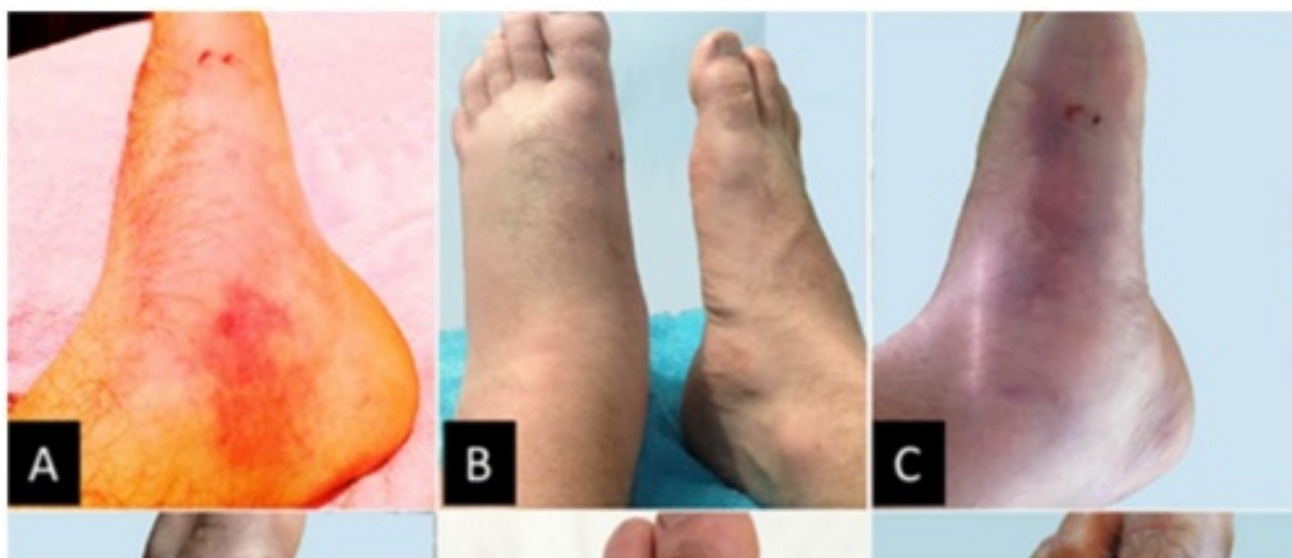

Figure 7. Schematic representation of the general catalytic mechanism of phosphohydrolase members of the HADSF. Catalysis proceeds through an aspartyl-phosphate intermediate. Source: <https://doi.org/10.1007/s00253-021-11547-w>.

3. Possible practical applications: Microbial 5'-nucleotidases: their characteristics, roles in cellular metabolism [19-20]

Even proteins isolated from mucus and venom cannot simply be assumed to originate from the stingrays themselves. As they may be secreted bacterial proteins, the biological origins of the stingray mucus proteins need to be identified (Figure 8) [21-23].



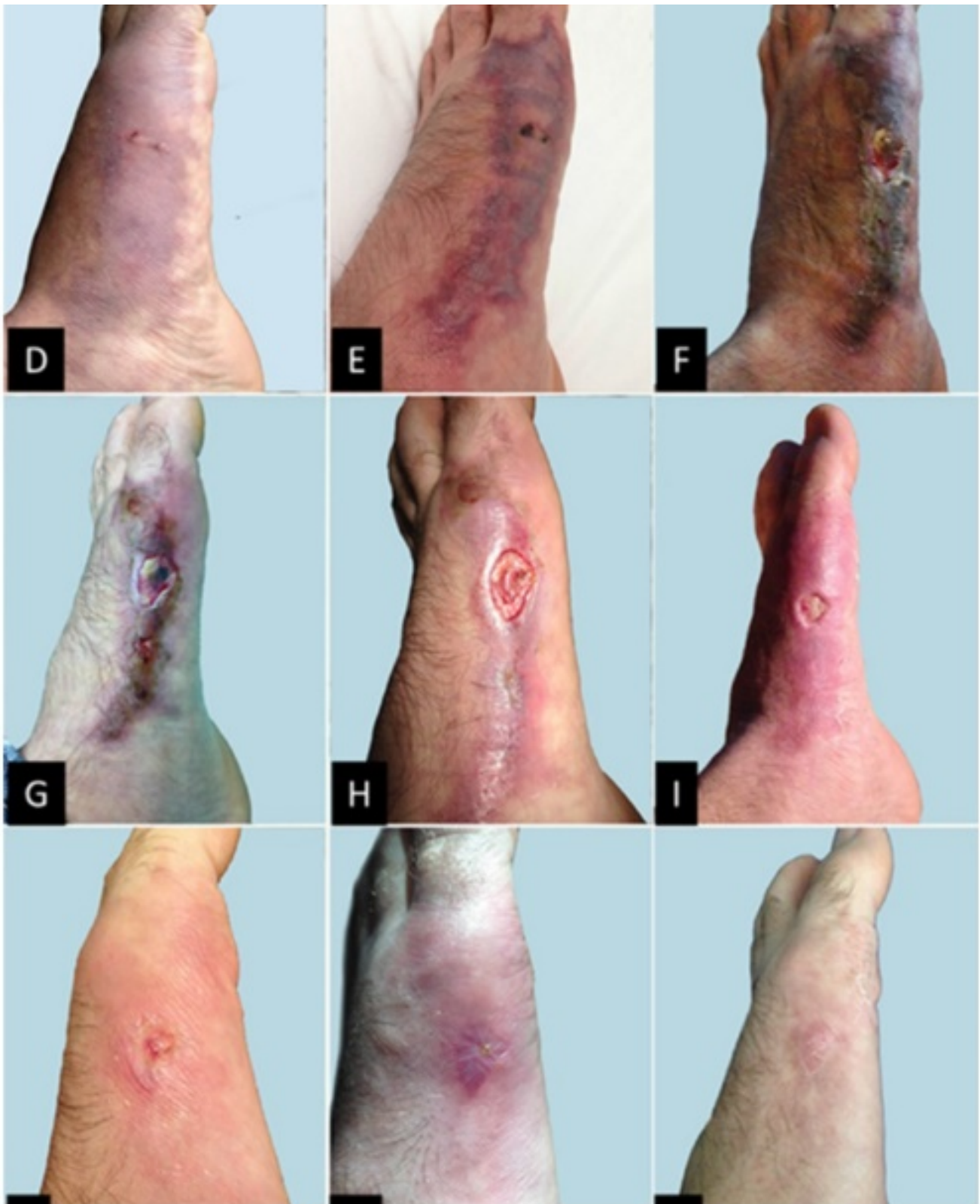


Figure 8. Evolution of the accident caused by an ocellate river stingray Evolution of the accident caused by an ocellate river stingray *Potamotrygon motoro* (Müller and Henle, 1841) (Chondrichthyes: Potamotrygonidae) from the first day to complete healing of the wound: A. Evident edema with vasculitis and hyperemia caused by the trauma of sting penetration with laceration of tissues, and by the action of proteolytic enzymes that damage cells and release fluid and cellular debris

into the interstices; B. Worsening of edema 24 h after the accident; C. Evident ecchymosis and prevailing edema; D. Worsening of ecchymosis; E. Ecchymosis with evident initial local necrosis; F. Dry necrosis of the affected area with evident dead tissue; G. Replacement of necrotic tissues with granulation tissue, although with areas of dead tissue; H. Total replacement of necrotic area with granulation tissue and evident recovery; I. Accelerated granulation of the affected area with only the focal trauma remaining open; J. to L. Total recovery of tissues and regeneration of the traumatized area. from the first day to complete healing of the wound: A. Evident edema with vasculitis and hyperemia caused by the trauma of sting penetration with laceration of tissues, and by the action of proteolytic enzymes that damage cells and release fluid and cellular debris into the interstices; B. Worsening of edema 24 h after the accident; C. Evident ecchymosis and prevailing edema; D. Worsening of ecchymosis; E. Ecchymosis with evident initial local necrosis; F. Dry necrosis of the affected area with evident dead tissue; G. Replacement of necrotic tissues with granulation tissue, although with areas of dead tissue; H. Total replacement of necrotic area with granulation tissue and evident recovery; I. Accelerated granulation of the affected area with only the focal trauma remaining open; J. to L. Total recovery of tissues and regeneration of the traumatized area. Source: Toxins (Basel). 2015 Jun 18;7(6):2272-88. doi: 10.3390/toxins7062272.

References

- [1] Haddad Junior V, Pardal PPO, Cardoso JLC, Martins IA. The venomous toadfish *Thalassophryne nattereri* (Niquim or Miquim): report of 43 injuries provoked in fishermen of Salinópolis (Pará State) and Aracaju (Sergipe State), Revista do Instituto de Medicina Tropical de São Paulo. 2003; 45(4): 221-223.
- [2] Haddad Jr V. Atlas of dangerous aquatic animals in Brazil: a medical guide to identification and treatment. 1st ed. São Paulo: Roca, 2000.
- [3] Lima LAF, Ferreira ML. Clinical and experimental studies on poisoning caused by the fish *Thalassophryne nattereri* (niquim). Brazilian Annals of Dermatology. 2000; 75: 435-443.
- [4] Lopes-Ferreira M, et al. *Thalassophryne nattereri* fish venom: biological and biochemical characterization and neutralization of its toxic activities. Toxicon. 1989; 36: 405-410.
- [5] Lopes-Ferreira M. *Thalassophryne nattereri* (niquim): from poison to therapy. [P.h.D. dissertation]: São Paulo: University of São Paulo; 2000.
- [6] Cury C. Butantan Institute produces serum to neutralize venomous fish poison [Internet]. São Paulo: Instituto Butantan; @2005 [cited 2024 Apr 26]. Available from <https://www.saopaulo.sp.gov.br/eventos/instituto-butantan-produz-soro-para-neutralizar-veneno-de-peixe-peconhento/>.
- [7] Junior V. Aquatic animals are of medical importance in Brazil. Journal of the Brazilian Society of Tropical Medicine. 2003; 36(5): 591-597.
- [8] Rensch GP, Elston DM. Aquatic antagonists: stingray injury update. Cutis. 2019; 103(3): 138-140.
- [9] Carmo LSS, Mota AON, Manoel CAF. Hemopneumothorax due to an accident with a freshwater stingray in the

Amazon region. *Pediatric Residency*. 2018; 8(1): 51-54.

[10] Reckziegel GC, Dourado FS, Garrone Neto D, Haddad Junior V. Injuries caused by aquatic animals in Brazil: an analysis of the data present in the information system for notifiable diseases. *Journal of the Brazilian Society of Tropical Medicine*. 2015; 48(4): 460-467.

[11] Silva NJJ, Ferreira KRC, Pinto RNL, Aird SD. A severe accident caused by an Ocellate River Stingray (*Potamotrygon motoro*) in Central Brazil: how well do we understand stingray venom chemistry, envenomation, and therapeutics? *Toxins (Basel)*. 2015; 7(6): 2272-2288.

[12] Haddad VJ, Garrone Neto D, Paula Neto JB, Marques FPL, Barbaro KC. Freshwater stingrays: study of the epidemiologic, clinic, and therapeutic aspects based on 84 envenomings in humans and some enzymatic activities of the venom. *Toxicon*. 2004; 43(3): 287-94.

[13] Santos JM, et al. Stingray (*Potamotrygon rex*) maturity is associated with the inflammatory capacity of the venom. *Toxicon*. 2019; 163: 74-83.

[14] Haddad Junior V, Lima C, Lopes-Ferreira M. Venomous freshwater fish: catfish and freshwater stingrays. In: Haddad Junior V, Gopalakrishnakone P, eds. *Marine and freshwater toxins*. 1st ed. New York: Springer; 2015. p. 445-451.

[15] Haddad Junior V, Cardoso JLC, Garrone Neto D. Injuries by marine and freshwater stingrays: history, clinical aspects of the envenomations and current status of a neglected problem in Brazil. *Journal of Venomous Animals and Toxins including Diseases Tropical*. 2013; 19(1): 16.

[16] Domingos MO, et al. The influence of environmental bacteria in freshwater stingray wound-healing. *Toxicon*. 2011; 58(2):147-53

[17] Monteiro WM, Oliveira SS, Sachett JAG, Silva IM, Ferreira LCL, Lacerda MVG. Hallux amputation after a freshwater stingray injury in the Brazilian Amazon. *Journal of the Brazilian Society of Tropical Medicine*. 2016; 49(3): 389-392.

[18] da Silva NJ Jr, Ferreira KR, Pinto RN, Aird SD. A Severe accident caused by an Ocellate River stingray (*Potamotrygon motoro*) in Central Brazil: How well do we understand stingray venom? Chemistry, Envenomation, and Therapeutics? *Toxins (Basel)*. 2015; 7(6): 2272-2288.

[19] Silva F, Huang Y, Yang V, Mu X, Shi Q, Antunes A. Transcriptomic characterization of the south american freshwater stingray *Potamotrygon motoro* venom apparatus. *Toxins (Basel)*. 2018; 10(12): 544.

[20] Magalhães KW, Lima C, Piran-Soares AA, Marques EE, Hiruma-Lima CA, Lopes-Ferreira M. Biological and biochemical properties of the Brazilian *Potamotrygon* stingrays: *Potamotrygon* cf. *scobina* and *Potamotrygon* gr. *orbignyi*. *Toxicon*. 2006; 47(5): 575-83.

[21] Dos Santos JC, Grund LZ, Seibert CS, Marques EE, Soares AB, Quesniaux VF, Ryffel B, Lopes-Ferreira M, Lima C. Stingray venom activates IL-33 producing cardiomyocytes, but not mast cell, to promote acute neutrophil-mediated injury.

Scientific Reports. 2017; 7(1): 7912.

[22] Zakataeva NP. Microbial 5'-nucleotidases: their characteristics, roles in cellular metabolism, and possible practical applications. *Applied Microbiology and Biotechnology*. 2021; 105: 7661–7681.

[23] da Silva NJ Jr, Ferreira KR, Pinto RN, Aird SD. A Severe accident caused by an Ocellate River Stingray (*Potamotrygon motoro*) in Central Brazil: How well do we really understand stingray venom chemistry, envenomation, and therapeutics? *Toxins (Basel)*. 2015; 7(6): 2272-2288.